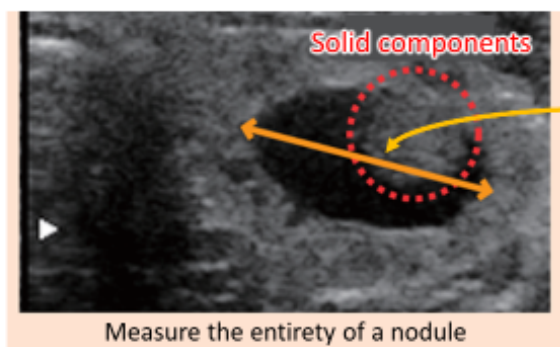


Cysts with solid components are all judged as nodules.

When the maximum size of a nodule with solid and cystic components (the length of the orange arrow) is 5.1 mm or larger, the examinee is diagnosed as Grade B.

- "Cysts with solid components," which are cysts containing nodules inside, are all evaluated as nodules in this examination.
- In such case, not the size of a nodule inside but the maximum size of a cyst with the nodule is recorded. For example, when a 3 mm-nodule is found in a 30 mm-cyst, the relevant examinee is judged to have a 30 mm-nodule and is diagnosed as Grade B (as the size exceeds 5.1 mm).

Prepared based on the website of the Radiation Medical Science Center for the Fukushima Health Management Survey, Fukushima Medical University (Information on the Thyroid Ultrasound Examination, FAQs)

Some cysts contain nodules. In the Thyroid Ultrasound Examination conducted in the Fukushima Health Management Survey, those cysts with solid components (nodules) are all judged as nodules and diagnosis criteria for nodules are applied.

For example, a 30 mm-cystic lesion with a 3 mm-solid component is judged as a nodule and diagnosis criteria for nodules are applied. As the size is larger than 5.1 mm, the examinee is diagnosed as Grade B and is advised to receive the Confirmatory Examination.

Lesions judged as fluid-only cysts are considered to be benign.
(Related to p.132 of Vol. 2, "Thyroid Ultrasound Examination: Cysts")

Included in this reference material on March 31, 2016

Updated on March 31, 2022