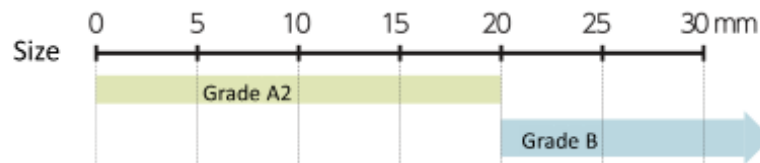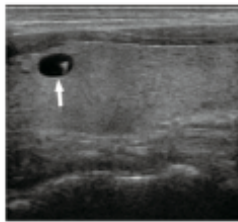


Thyroid Ultrasound Examination: Cysts

A cyst, which resembles a bag filled with fluid, is generally benign, and is often found even in healthy people

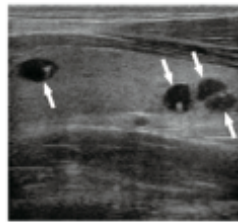


Cysts are generally benign, but those of 20 mm or larger may cause a feeling of pressure in the throat and fluid in a cyst is sometimes withdrawn.



Single cyst

* The parts pointed with arrows are cysts.



Multiple cysts

- A cyst, which resembles a bag filled with fluid, is benign, and is often found even in healthy people.
- Cysts often change in size or number, and many people have multiple cysts.
- Examinations so far revealed that cysts are seldom found in infants and young children but are found more often in elementary, junior high, and high school students.

Prepared based on the Report on the Fukushima Prefecture's Fukushima Health Management Survey (FY2021)

Cysts identified in the Thyroid Ultrasound Examination being conducted in Fukushima Prefecture are considered benign, consisting only of fluid and containing no cells. They are often found even in healthy people, especially among primary and secondary school students. Therefore, repeated examinations often find cysts as children grow up.

Included in this reference material on March 31, 2013

Updated on March 31, 2023