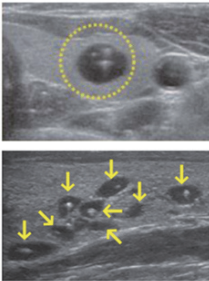
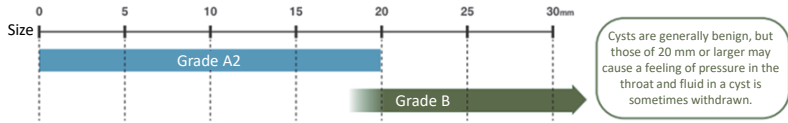


Thyroid Examination: Cysts

A cyst, which resembles a bag filled with fluid, is generally benign, and is often found even in healthy people.



- Cysts often change in size or number.
- Many people have multiple cysts, and the estimated size of the largest one is told to each examinee in this examination.
- Cysts consisting only of fluid and containing no cells are not cancerous.
- Cysts found in the latest examination were all deemed to be benign.
- Cysts are seldom found in babies and infants but are rather found in primary and secondary school students.

Prepared based on the website of the Radiation Medical Science Center for the Fukushima Health Management Survey, Fukushima Medical University, "Q&A on the Thyroid Examination"

Cysts identified in the Thyroid Examination being conducted in Fukushima Prefecture are considered benign, consisting only of fluid and containing no cells. They are often found even in healthy people, especially among primary and secondary school students. Therefore, repeated examinations often find cysts as children grow up.

Included in this reference material on March 31, 2013

Updated on March 31, 2017